

Effects of modified and conventional facemask therapies with expansion on dynamic measurement of natural head position in Class III patients

Ahmet Yagci,^a Tancan Uysal,^b Serdar Usumez,^c and Metin Orhan^d
Kayseri, Izmir, Gaziantep, and Ankara, Turkey

Introduction: The aim of this prospective clinical trial was to assess the effects of varying force directions on the dynamic measurement of natural head position and orofacial airway dimensions of Class III patients during maxillary orthopedic protraction compared with an untreated control group. **Methods:** The conventional facemask group comprised 15 patients (8 girls, 7 boys; mean age, 9.6 ± 1.3 years), the modified facemask group comprised 15 patients (7 girls, 8 boys; mean age, 9.5 ± 1.5 years), and the control group comprised 15 subjects (7 girls, 8 boys; mean age, 9.8 ± 1.6 years). Natural head position measurements and cephalometric records were obtained from all subjects before and after treatment or the control period (approximately 1 year). An inclinometer and a portable data logger were used to collect the dynamic natural head position data. For statistical comparisons, paired samples *t* tests, analysis of variance (ANOVA), and post-hoc Tukey tests were used at the $P < 0.05$ level. **Results:** Both treatment groups showed statistically significant changes in the sagittal (pitch) measurements of natural head position and upper pharynx, aerial, and total area of airway measurements during the treatment period. In the control group, the only statistically significant change was an increased upper pharynx measurement ($P = 0.020$). According to the intergroup comparisons, statistically significant natural head position differences were found in the conventional (6.4° flexion) and the modified (5.7° flexion) facemask groups when compared with the controls. The modified facemask group also showed significant changes in aerial ($P = 0.003$) and total ($P < 0.001$) areas of the airway measurements compared with the control group. No statistically significant differences were observed between the 2 treatment groups. **Conclusions:** These findings suggest that modified and conventional facemask therapy with expansion have significant cranial flexion effects on the dynamic measurements of natural head position. Additionally, the modified facemask procedure showed significant effects on the orofacial airway dimensions compared with the initial values and the values of the untreated controls. (Am J Orthod Dentofacial Orthop 2011;140:e223-e231)

Facemask and palatal expansion therapy has become a common technique for the correction of developing Class III malocclusions in recent years.

^aAssistant professor, Department of Orthodontics, Faculty of Dentistry, Erciyes University, Kayseri, Turkey.

^bProfessor and chair, Department of Orthodontics, Faculty of Dentistry, Izmir Katip Celebi University, Izmir, Turkey; professor, Department of Pediatric Dentistry and Orthodontics, College of Dentistry, King Saud University, Riyadh, Saudi Arabia.

^cProfessor and chair, Department of Orthodontics, Faculty of Dentistry, Gaziantep University, Gaziantep, Turkey.

^dProfessor, Department of Orthodontics, Faculty of Dentistry, Gazi University, Ankara, Turkey.

The authors report no commercial, proprietary, or financial interest in the products or companies described in this article.

Reprint requests to: Tancan Uysal, Izmir Katip Celebi Üniversitesi Diş Hekimliği Fakültesi, Ortodonti A.D., Izmir, Turkey; e-mail, tancanuysal@yahoo.com.

Submitted, December 2010; revised and accepted, May 2011.

0889-5406/\$36.00

Copyright © 2011 by the American Association of Orthodontists.

doi:10.1016/j.ajodo.2011.05.018

Studies have documented that facemask treatment before adolescence produces an orthopedic effect to bring the maxilla forward (with counterclockwise rotation), often accompanied by a downward-backward rotation of the mandible and favorable dental changes for correction of reverse overjet and Class III malocclusion.¹

Counterclockwise rotation of the maxilla is a benefit in the treatment of low-angle, deepbite Class III patients, but it is not recommended in Class III patients with high-angle skeletal patterns and anterior open bites.² To eliminate these undesired side effects, some investigators have applied the protraction force close to the center of resistance of the maxilla with a modified face-bow. Investigators showed that a modified facemask application method with a face-bow is an effective way to prevent counterclockwise rotation of the maxilla.^{2,3}

Profitt and Fields⁴ claimed that rapid maxillary expansion (RME) had to be done before protraction of the maxilla. Other studies in the literature support the concept that RME treatment releases the maxilla's sutures with the surrounding bones and enhances the protraction procedure.^{5,6} RME can also cause a total increase in the nasal cavity's volume, since its lateral walls are displaced apart. A possible hypothesis about the role of facemask and palatal expansion therapy in postural changes might be that the increased palatal diameter results in the consequent enlargement of the pharyngeal airway space. This enlargement leads to improvement in respiratory function and consequent flexion of the head on the cervical column with an increase of the cervical lordosis angle and a decrease of the craniocervical angulations.⁷

Various methods can obtain natural head position.⁸⁻¹⁰ Some authors accept natural head position as the most relaxed position of the head when the subject is not guided by any outer reference (self-balanced position).¹¹⁻¹³ Others believe that natural head position is the position of the head when the subject's visual axis is parallel to the ground.⁸ Orhan and Goyenc¹⁴ produced natural head position by the "target on the mirror" technique with high reproducibility but stated that it was an unnatural, forced, and static position. In addition, natural head position is described not as a single angular measurement but as a small range of angles around the natural head position.^{14,15} Thus, this position is dynamic and should be recorded as such.

To our knowledge, the effects of modified and conventional facemask therapies with expansion on the dynamic measurements of natural head position and orofacial airway dimensions compared with a control group have not been studied. The aim of this prospective clinical trial was to assess the effects of varying force directions on natural head position and orofacial airway changes with maxillary orthopedic protraction compared with a control group. The null hypothesis assumed that there were no statistically significant changes in natural head position and orofacial airway dimensions after treatment with conventional and modified facemasks and expansion therapy compared with the controls.

MATERIAL AND METHODS

This study was approved by the Regional Ethical Committee on Research of the Erciyes University in Turkey.

A power analysis established by G*Power software (version 3.0.10; Franz Faul, Universität Kiel, Kiel, Germany), based on a 1:1 ratio between groups and a sample size of 15 patients, would give more than 75% power to

detect significant differences with an effect size of 0.30 and $\alpha = 0.05$ significance level.

Our sample consisted of the dynamic natural head position records of 45 Class III patients with maxillary retrusion. Patients who satisfied the following inclusion criteria were selected: (1) Class III molar relationship, (2) anterior crossbite or edge-to-edge incisal relationship, (3) ANB angle of 0° or less and nasion perpendicular to A-point of 2 mm or less, (4) no congenitally missing or extracted teeth, and (5) no deformity in the nasomaxillary complex.

Patients with craniofacial abnormality, psychosocial impairment, craniofacial anomaly, skeletal openbite, nasal allergic conditions, airway obstructions due to adenoids, or previous orthodontic treatment were excluded from the study.

The conventional facemask group comprised 15 patients (8 girls, 7 boys; mean age, 9.6 ± 1.3 years), the modified facemask group comprised 15 patients (7 girls, 8 boys; mean age, 9.5 ± 1.5 years), and the control group comprised 15 subjects (7 girls, 8 boys; mean age, 9.8 ± 1.6 years). Treatment times in group 1 were between 0.6 and 1.5 years (mean, 1.12 ± 0.24 years); treatment times in group 2 were between 0.7 and 1.7 years (mean, 1.24 ± 0.4 years); and the observation period in the control group was between 0.5 and 1.6 years (mean, 0.97 ± 0.32 years).

To constitute the control group, dynamic records of natural head position were taken with parental permission by obtaining informed consent from subjects or parents who did not accept treatment with an extraoral appliance at that time.

In the conventional facemask group, a facemask¹⁶ and a bonded full-coverage maxillary acrylic splint expander with vestibular hooks and heavy elastics (500 g, depending on the distance between the hooks of the expansion appliance and the facemask) were used for orthopedic therapy.¹

Elastics were connected bilaterally to the adjustable midline crossbow on the Petit-type facemask.¹⁶ The protraction elastics were applied to the vestibular hooks attached between the lateral incisors and the canines above 10 to 15 mm to the maxillary occlusion plane, with a downward and forward pull of 20° to prevent bite opening during maxillary protraction.

In the modified facemask group, a modified bonded RME appliance with full occlusal coverage, a specially designed facebow, a facemask, and heavy elastics (500 g, depending on the distance between the modified face-bow hook parts and the facemask) were used for orthopedic facemask therapy.

The bonded expansion appliance was modified by adding 2 tubes (Activator tubes; Dentaaurum, Ispringen,

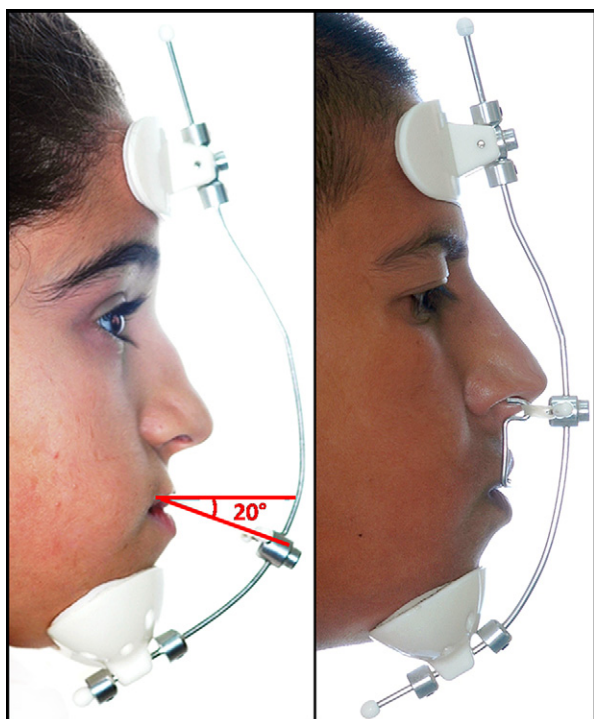


Fig 1. Facemasks used in this study.

Germany) on the buccal side of the acrylic in the premolar area. The purpose of these tubes was to accommodate the inner bows of the specially designed face-bow. The face-bow was constructed from an adjustable face-bow (standard stainless steel, G&H Wire, Franklin, Ind). The inner bows of the face-bow end went in the mouth with a special U-shape bend to enter the buccal tubes from the distal aspect and thus to retain it when an anterior pull was applied. The outer bow was bent upward at 90° to provide a point of force application at the level of the dentomaxillary center of resistance and also to apply the parallel forces in both sides (Fig 1).

In both treatment groups, the midline expansion screw of the bonded maxillary expander was activated twice a day for the first week and once a day until the desired change in the transverse dimension was achieved. The patients were instructed to wear the facemask full time except during meals. We told the patients to keep track of their wearing time on the scorecard and to bring the card to each visit. The appliance was used in both treatment groups until a positive overjet was accomplished.

An inclinometer (linear tilt sensor, SX-070DLIN; Advanced Orientation Systems, Linden, NJ) and a portable data logger (XR440; Pace Scientific, Mooresville, NC) were used to collect the dynamic head posture data as




Fig 2. Instruments used in study: A, eyeglass frame with inclinometers; B, conversion module; C, data logger; D, personal computer connection cable. A, B, and C were worn, and D was unplugged from the logger during walking.



Fig 3. Cranial portion of the device. Note the placement of the inclinometers on opposite sides.

described previously (Figs 2 and 3).¹⁷ The inclinometers were placed on the eyeglasses' arms, and cables from the inclinometers to the data logger were positioned not to obstruct the subject's field of view. The right sensor was positioned parallel to the sagittal plane to determine changes in pitch, and the left sensor was positioned vertical to the sagittal plane to determine changes in roll. Analog data were used to record the dynamic changes in head position, and the data were stored in a portable data logger. The sampling rate of the data logger was adjusted to 1 sample every 2 seconds for a recording period of 6 minutes. The mean dynamic natural head

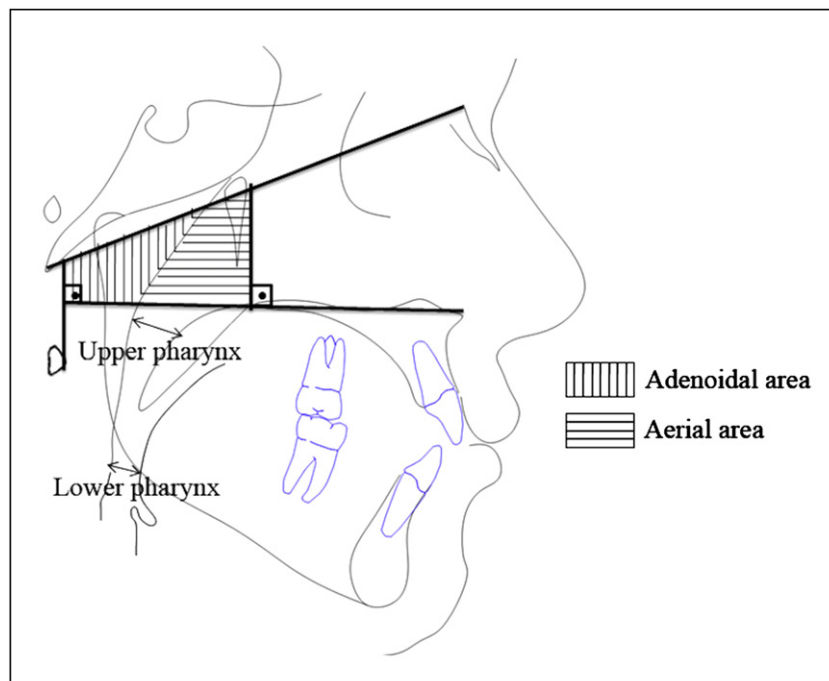


Fig 4. Cephalometric measurements used in the study.

Table I. Bland-Altman plot to assess the repeatability

| Measurements | Correlation | Bias | 95% CI | SE | SD of differences |
|----------------|-------------|-------|------------------|------|-------------------|
| Upper pharynx | 0.50 | −0.27 | −0.684 to 0.146 | 0.19 | 0.78 |
| Lower pharynx | 0.04 | −0.29 | −0.566 to −0.006 | 0.13 | 0.53 |
| Adenoidal area | 0.13 | −0.30 | −1.7 to 1.0 | 0.63 | 2.50 |
| Aerial area | 0.04 | −6.02 | −10.10 to −1.94 | 1.91 | 7.66 |
| Total area | 0.01 | −6.37 | −10.17 to −2.57 | 1.78 | 7.13 |

position was calculated for each subject by using the collected data. When the head is tipped forward in the sagittal plane relative to the true vertical, the value measured by the inclinometers is positive. A negative value shows backward tipping.

The natural head position recordings were collected at the initial stage of the appliance placement and at the end of the facemask and palatal expansion therapy (mean treatment periods, 1.12 ± 0.24 years for the conventional facemask group and 1.24 ± 0.40 years for the modified facemask group). Natural head position records from the control group were taken approximately 1 year after the initial records, similar to the treatment group (mean observation period, $0.97 \text{ years} \pm 0.32$ months). All natural head position recordings in the study groups were taken from the patients without the RME and facemask appliances in situ.

Lateral cephalometric radiographs were taken with a cephalometer (Ortoceph OC100, Instrumentarium,

Tuusula, Finland). All subjects were positioned in the cephalostat with the sagittal plane at a right angle to the path of the x-rays, the Frankfort plane was parallel to the horizontal, the teeth were in centric occlusion, and the lips were lightly closed.

All radiographs were traced manually, and whole measurements were recorded by an author (A.Y.) and reviewed twice by another investigator (T.U.) for accurate landmark identification.

The following cephalometric measurements were made (Fig 4): (1) McNamara's upper pharynx dimension: the minimum distance between the upper soft palate and the nearest point on the posterior pharynx wall¹⁸; (2) McNamara's lower pharynx dimension: the minimum distance between the point where the posterior tongue contour crosses the mandible and the nearest point on the posterior pharynx wall¹⁸; and (3) total, adenoidal, and aerial areas by using the method of Handelman and Osborne.¹⁹ This method takes as references the

Table II. Pretreatment and control measurements and statistical comparisons

| | CFM group (pretreatment) | | MFM group (pretreatment) | | Control group (initial) | | P |
|--|--------------------------|------|--------------------------|------|-------------------------|------|-------|
| Measurement | Mean | SD | Mean | SD | Mean | SD | |
| Natural head position measurements | | | | | | | |
| Transversal (roll) (°) | 9.2 | 2.1 | 5.3 | 11.8 | 3.2 | 11.9 | 0.388 |
| Sagittal (pitch) (°) | −6.3 | 6.4 | −8.8 | 9.7 | 1.4 | 11.4 | 0.056 |
| Skeletal measurements | | | | | | | |
| SNA (°) | 77.1 | 1.5 | 77.3 | 2.1 | 77.8 | 2.0 | 0.544 |
| SNB (°) | 79.8 | 2.3 | 80.2 | 2.4 | 79.9 | 2.2 | 0.680 |
| ANB (°) | −2.7 | 1.4 | −2.9 | 2.2 | −2.1 | 1.7 | 0.154 |
| SN-MP (°) | 35.4 | 2.5 | 34.6 | 3.4 | 34.9 | 2.7 | 0.241 |
| SN-PP (°) | 9.5 | 3.6 | 9.2 | 3.2 | 9.4 | 3.1 | 0.169 |
| A to N perp (mm) | −2.8 | 1.8 | −3.1 | 2.4 | −2.2 | 1.9 | 0.174 |
| Pg-Na Perp (mm) | −1.1 | 3.4 | −0.8 | 4.1 | −0.5 | 3.7 | 0.632 |
| Dental measurements | | | | | | | |
| Interincisal angle (°) | 132.8 | 11.2 | 137.1 | 11.8 | 136.3 | 9.9 | 0.089 |
| U1-NA (mm) | 3.3 | 1.7 | 4.0 | 2.2 | 2.9 | 2.4 | 0.076 |
| U1-NA (°) | 24.3 | 6.1 | 26.3 | 7.1 | 23.9 | 8.3 | 0.321 |
| L1-NB (mm) | 2.9 | 1.4 | 2.2 | 1.2 | 2.7 | 1.3 | 0.678 |
| L1-NB (°) | 22.3 | 5.7 | 20.6 | 6.4 | 21.7 | 6.1 | 0.576 |
| Soft-tissue measurements | | | | | | | |
| UL to E plane (mm) | −3.5 | 1.9 | −4.0 | 2.1 | −4.1 | 2.2 | 0.746 |
| LL to E plane (mm) | 0.6 | 2.2 | 0.0 | 2.1 | −0.1 | 2.4 | 0.781 |
| CFM, Conventional facemask; MFM, modified facemask | | | | | | | |

CFM, Conventional facemask; MFM, modified facemask.

basion-nasion plane, the bispinal plane, and 2 perpendicular lines to the bispinal plane—1 crosses the more anterior point at the atlas vertebra and other crosses the posterior nasal spine. The resulting trapezoid is divided into 2 spaces (aerial and adenoid). Total area is the sum of adenoidal and aerial areas.

Statistical analysis

All statistical analyses were performed by using the Statistical Package for the Social Sciences (version 13.0 for Windows; SPSS, Chicago, Ill). The normality test of Shapiro-Wilks and the Levene variance homogeneity were applied to the data. The data were distributed normally, and there was homogeneity of variance between the groups. Descriptive statistics were given as mean and standard deviation. Intragroup comparisons were evaluated by using the paired samples *t* test, and intergroup changes were analyzed with analysis of variance (ANOVA). Post-hoc multiple comparisons were done by the Tukey honestly significance difference test. When the *P* value was less than 0.05, the statistical test was determined to be significant.

To determine the errors associated with the radiographic measurements, 10 radiographs were selected randomly. Their tracings were repeated 8 weeks after the first measurements. A Bland-Altman plot was applied to assess the repeatability. The differences between the first and second measurements were insignificant (Table I).

RESULTS

Descriptive pretreatment and control values of measurements and statistical comparisons are presented in Table II. Pretreatment and posttreatment and control descriptive statistical values and comparisons are given in Table III. Mean difference and standard deviations of the measurements and the post-hoc statistical comparisons are presented in Table IV.

To determine whether the 3 groups of subjects were matched, ANOVA was performed on the means of the pretreatment measurements. It was found that the 3 groups were equally matched because the totality of the measurements was not significantly different (Table II).

In the conventional facemask group, statistically significant changes were found in sagittal natural head position measurements (*P* = 0.009), and upper pharynx (*P* = 0.005), aerial area (*P* = 0.003), and total area (*P* = 0.030) measurements of the airway during the treatment period. In the modified facemask group, the posttreatment measurements showed significant differences in sagittal measurements of natural head position (*P* = 0.017) and upper pharynx (*P* = 0.005), aerial area (*P* < 0.001), and total area (*P* < 0.001) of the airway measurements. In the control group, the only statistically significant change was in the upper pharynx measurement (*P* = 0.020) (Table III).

In both facemask and expansion groups, changes in the sagittal mean values of the dynamic natural head

Table III. Values and standard deviations of the measurements and statistical comparisons

| Measurement | CFM group | | | | | MFM group | |
|-----------------------------------|--------------|--------|---------------|--------|----------|--------------|----------|
| | Pretreatment | | Posttreatment | | P value* | Pretreatment | |
| | Mean | SD | Mean | SD | | Mean | SD |
| Transversal (roll) (°) | 9.24 | 2.13 | 6.51 | 7.51 | 0.229 | 5.34 | 11.80 |
| Sagittal (pitch) (°) | −6.31 | 6.44 | 7.25 | 18.85 | 0.009 | −8.77 | 9.66 |
| Upper pharynx (mm) | 7.58 | 2.90 | 9.73 | −2.71 | 0.005 | 9.28 | 2.972274 |
| Lower pharynx (mm) | 10.69 | 2.98 | 10.50 | 2.20 | 0.813 | 10.76133 | 3.550758 |
| Adenoidal area (mm ²) | 311.82 | 154.11 | 303.27 | 149.20 | 0.712 | 220.9353 | 85.90047 |
| Aerial area (mm ²) | 478.83 | 132.76 | 604.95 | 157.76 | 0.003 | 376.132 | 90.99299 |
| Total area (mm ²) | 790.65 | 244.88 | 908.22 | 183.38 | 0.030 | 597.0673 | 128.1281 |

CFM, Conventional facemask; MFM, modified facemask.

*Paired samples *t* test.

position measurement were statistically significant when compared with the control group (conventional facemask vs control, $P = 0.016$; modified facemask vs control, $P = 0.033$). The modified facemask group also showed significant changes in aerial ($P = 0.003$) and total ($P < 0.001$) areas of the airway measurements compared with the control group. When both treatment groups were compared, no statistically significant differences were found in any measurements.

DISCUSSION

In this study, we used an inclinometer system to assess the effects of varying force directions on head position changes with maxillary orthopedic protraction compared with a control group. Significant natural head position differences were found in the conventional (6.4° flexion) and modified (5.7° flexion) facemask groups when compared with the control group. The modified facemask group also showed significant changes in aerial and total areas of the airway measurements compared with the control group. According to our findings, the null hypothesis was thus rejected.

Accurate registration of head position should be done with a measuring device that can make dynamic recordings. Recording head posture should be possible during swallowing and mastication. Ideally, this device should be easy to use and should not affect head position. At the same time, measurements should be reproducible over long periods, and the accuracy of the recordings should not depend entirely on operator skill. Murphy et al²⁰ constructed such a device by using a contactless, precision potentiometer capable of measuring single-axis angles. They found that the device could make continuous and accurate recordings of cranial posture. Preston et al²¹ used the same device for comparing head positions in standing and walking subjects, and suggested that the system could be used for positioning

patients, as in taking natural head position cephalometric radiographs. Another smaller and lighter device, introduced by Usume and Orhan,¹⁷ was shown to be effective in measurement and transfer of head posture. However, wearing the inclinometer apparatus might have an effect on natural head position. The head portion of the instrument used in this study was kept as light and small as possible to avoid affecting natural head position. The cranial portion of the instrument weighed only 21.6 g. Furthermore, Murphy et al²⁰ demonstrated that the inclinometer apparatus did not have a significant effect on the wearer's head posture.

It was shown that both sagittal and transversal natural head positions were reproducible after 2 years.²² Differential growth or local soft-tissue changes in the bridge of the nose and the superior auricular fornix (where the spectacles that carry the inclinometers rest) could change the seat of the spectacles for growing subjects. This might lead to overinterpretation or underinterpretation of the reproducibility of natural head position. However, many researchers confirmed that natural head position was reproducible for a relatively short term.^{10,13,22,23} In this study, the sample comprised 45 patients, 9.6 ± 1.4 years of age, who were treated or observed for about 1 year.

Cervical posture and the anatomy of the first cervical vertebra have been related to factors such as nasorespiratory function^{24,25} and orthodontic therapy.²⁶ The anatomy and position of the cervical curvature in space have been related to different factors concerning general aspects of the body, ethnicity,²⁷ sex,²⁷ and age.²⁸ Despite that, some researchers who investigated natural head position found insignificant sex differences.^{22,29} Therefore, sex differences were not determined in this study.

A review of the literature showed that greater skeletal changes with maxillary protraction appliances are possible in young patients.³⁰ On the other hand, Yuksel et al³¹

Table III. Continued

| <i>MFM group</i> | | | <i>Control group</i> | | | | |
|----------------------|-----------|-----------------|----------------------|-----------|----------------------|-----------|-----------------|
| <i>Posttreatment</i> | | | <i>Observation 1</i> | | <i>Observation 2</i> | | |
| <i>Mean</i> | <i>SD</i> | <i>P value*</i> | <i>Mean</i> | <i>SD</i> | <i>Mean</i> | <i>SD</i> | <i>P value*</i> |
| 6.96 | 5.41 | 0.890 | 3.23 | 11.89 | 6.79 | 10.00 | 0.583 |
| 6.25 | 24.57 | 0.017 | 1.37 | 11.39 | 0.86 | 10.52 | 0.326 |
| 10.96733 | −3.00794 | 0.005 | 8.591333 | 2.800398 | 9.614667 | −3.28113 | 0.020 |
| 10.96667 | 4.320702 | 0.880 | 11.47333 | 4.195368 | 11.05267 | 3.633777 | 0.669 |
| 259.696 | 90.78401 | 0.052 | 319.414 | 107.9055 | 301.4147 | 92.8669 | 0.094 |
| 555.1667 | 130.5534 | <0.001 | 531.3 | 143.7499 | 568.1627 | 150.56 | 0.135 |
| 814.8627 | 145.9195 | <0.001 | 850.714 | 174.2346 | 869.5773 | 175.0755 | 0.499 |

Table IV. Mean difference values and standard deviations of the measurements and statistical comparisons

| <i>Measurement</i> | <i>CFM group</i> | | <i>MFM group</i> | | <i>Control group</i> | | <i>Post-hoc test</i> | | |
|-----------------------------------|------------------|-----------|------------------|-----------|----------------------|-----------|----------------------|----------------------|----------------------|
| | | | | | | | <i>Groups</i> | | |
| | <i>MD</i> | <i>SD</i> | <i>MD</i> | <i>SD</i> | <i>MD</i> | <i>SD</i> | <i>(CFM-MFM)</i> | <i>(CFM-control)</i> | <i>(MFM-control)</i> |
| Transversal (roll) (°) | −2.73 | 7.96 | 1.62 | 14.57 | 3.56 | 11.93 | NS | NS | NS |
| Sagittal (pitch) (°) | 13.56 | 20.22 | 15.01 | 23.61 | −0.51 | 5.84 | 0.982 | 0.016 | 0.033 |
| Upper pharynx (mm) | 2.15 | 2.50 | 1.69 | 1.94 | 1.02 | 1.52 | NS | NS | NS |
| Lower pharynx (mm) | −0.19 | 2.97 | 0.21 | 5.15 | −0.42 | 3.73 | NS | NS | NS |
| Adenoidal area (mm ²) | −8.55 | 84.93 | 38.76 | 68.35 | −18.00 | 37.43 | NS | NS | NS |
| Aerial area (mm ²) | 126.12 | 137.70 | 179.04 | 91.12 | 36.86 | 89.89 | 0.384 | 0.074 | 0.003 |
| Total area (mm ²) | 117.57 | 171.05 | 217.80 | 92.74 | 18.86 | 105.14 | 0.092 | 0.099 | <0.001 |

CFM, Conventional facemask; MFM, modified facemask; MD, mean difference; NS, not significant.

compared the treatment outcomes in 2 chronologic age groups and found no significant difference in the orthodontic and orthopedic effects. According to Merwin et al,³² there was no difference between the age groups of 5 to 8 and 8 to 12 years from the point of protraction of the maxilla. Taylor et al³³ concluded that greater rates of change in the soft-tissue measurements of the posterior pharyngeal wall occurred between 6 to 9 years and 12 to 15 years, and that growth increments were small between 9 and 12 years. Because the mean age of the subjects in our study was 9.6 years and the mean treatment time was about 1 year, it was thought that the changes in pharyngeal measurements related to normal growth were negligible.

The breathing pattern might influence the development of the transverse relationship, resulting in the development of posterior crossbite.³⁴ Ceylan and Oktay³⁵ reported that the pharyngeal airway size was influenced by the changes in ANB angle. Hiyama et al³⁶ found that maxillary growth induced by protraction treatment had a significant positive effect on the superior upper airway dimension. Oktay and Ulukaya³⁷ found that maxillary

protraction increased the distances and increments in the upper part of the airway space. Sayinsu et al³⁸ investigated the effects of RME and a protraction appliance on the sagittal airway, and found an increase in nasopharyngeal width. Similarly, Kilinc et al³⁹ demonstrated that maxillary expansion together with protraction of the maxilla improved nasopharyngeal and oropharyngeal airway dimensions. Kaygisiz et al⁴⁰ evaluated the long-term outcomes of treatment with reverse headgear in patients with skeletal Class III malocclusion. They found that the nasopharyngeal airway dimensions were improved after treatment, and favorable effects of the treatment remained over the posttreatment period of 4 years. Similarly, in our study, both treatment groups showed increases in the aerial and total areas of the airway during the treatment period. However, according to intergroup comparisons, significant differences were observed only in the modified facemask and expansion group compared with the control group. A different rotational pattern of the maxilla during the protraction procedure might explain the differences in airway changes.

On the other hand, Mucedero et al⁴¹ analyzed the effects of RME and facemask, or facemask combined with bite-block, on the sagittal pharyngeal dimensions in subjects with Class III malocclusion compared with an untreated Class III control group. They found that the favorable skeletal maxillary and mandibular changes produced by maxillary protraction with or without RME were not associated with significant changes in the sagittal oropharyngeal and nasopharyngeal airway dimensions, and orthopedic treatment of Class III malocclusion did not produce a significant increase in airway dimensions in the short term. Baccetti et al⁴² found no significant short-term or long-term changes in the sagittal oropharyngeal and nasopharyngeal airway dimensions induced by maxillary protraction in subjects with a Class III malocclusion when compared with untreated control group. When compared with the control group, only the modified facemask group showed statistically significant differences in aerial and total area measurements in this study.

Respiratory airway function influences facial morphology and craniofacial functions.⁴³ It has been commonly accepted that there is a relationship between head posture and upper airway size.^{36,37} Upper airway enlargement leads to improvement in respiratory function and consequent flexion of the head.⁷ In our study, in the modified facemask and expansion group, aerial and total airway measurements had statistically significant increases. We thought that, as a result of these airway increases during expansion and protraction of the maxilla, statistically significant amounts of cranial flexion of natural head position were found in both treatment groups (6.4° flexion in the conventional facemask group and 5.7° flexion in the modified facemask group).

In the modified facemask group, pharyngeal airway space was increased with protraction and expansion therapy, and natural head position was changed comparably. Although a significant flexion of head posture was determined (mean, 6.4°) in the conventional facemask group, no statistically significant changes were found in pharyngeal airway space compared with the untreated control group. Changes in body posture have been shown to elicit activity from muscles that could affect the mandibular rest position.^{44,45} This circumstance might be the result of relationships between natural head position and mandibular rest position.

CONCLUSIONS

Within the limitations of this study, these findings suggest that modified and conventional facemask therapy with expansion had significant cranial flexion effects on the dynamic measurements of natural head position.

Additionally, the modified facemask procedure showed significant effects on orofacial airway dimensions compared with the initial values and the values of the untreated controls.

REFERENCES

1. McNamara JA Jr, Brudon WL. Orthodontic and orthopedic treatment in the mixed dentition. Ann Arbor, Mich: Needham Press; 1993.
2. Keles A, Tokmak EC, Erverdi N, Nanda R. Effect of varying the force direction on maxillary orthopedic protraction. *Angle Orthod* 2002; 72:387-96.
3. Göyenc Y, Ersoy S. The effect of a modified reverse headgear force applied with a facebow on the dentofacial structures. *Eur J Orthod* 2004;26:51-7.
4. Proffit WR, Fields HW Jr. Contemporary orthodontics. St Louis: Mosby; 1993.
5. Nanda R. Biomechanical and clinical considerations of a protraction headgear. *Am J Orthod* 1980;78:125-39.
6. Haas AJ. The treatment of maxillary deficiency by opening the midpalatal suture. *Angle Orthod* 1965;16:200-17.
7. Tecco S, Festa F, Tete S, Longhi V, D'Attilio M. Changes in head posture after rapid maxillary expansion in mouth-breathing girls: a controlled study. *Angle Orthod* 2005;75:171-6.
8. Marcotte MR. Head posture and dentofacial proportions. *Angle Orthod* 1981;51:208-13.
9. Showfety KJ, Vig PS, Matteson S. A simple method for taking natural head position cephalograms. *Am J Orthod* 1983;83: 495-500.
10. Sandham A. Repeatability of head posture recordings from lateral cephalometric radiographs. *Br J Orthod* 1988;15:157-62.
11. Solow B, Tallgren A. Natural head position in standing subjects. *Acta Odontol Scand* 1971;29:591-607.
12. Solow B, Tallgren A. Dentoalveolar morphology in relation to craniocervical posture. *Angle Orthod* 1977;47:157-64.
13. Moorrees CFA, Kean MR. Natural head position, a basic consideration in the interpretation of cephalometrics radiographs. *Am J Phys Anthropol* 1958;16:213-34 (cited in: Cooke MS, Wei SH. A summary five-factor cephalometric analysis based on natural head posture and the true horizontal. *Am J Orthod Dentofacial Orthop* 1988;93:213-23).
14. Orhan M, Goyenc YB. Determination of natural head position with "target on the mirror" technique [thesis]. Konya, Turkey: Selçuk University Health Sciences Institute; 1996.
15. Lundström A. Natural head position: a discussion of the concepts. *Br J Orthod* 1990;17:249-50.
16. Petit H. Adaptations following accelerated facial mask therapy. In: McNamara JA, Ribbens KA, Howe RP, editors. Clinical alteration of the growing face. Monograph 14. Craniofacial Growth Series. Ann Arbor: Center for Human Growth and Development; University of Michigan; 1983. p. 48-59.
17. Usumez S, Orhan M. Inclinator method for recording and transferring natural head position in cephalometrics. *Am J Orthod Dentofacial Orthop* 2001;120:664-70.
18. McNamara JA. A method of cephalometric evaluation. *Am J Orthod* 1984;86:449-69.
19. Handelman CS, Osborne G. Growth of the nasopharynx and adenoid development from one to eighteen years. *Angle Orthod* 1976;46:243-59.
20. Murphy KE, Preston CB, Evans WG. The development of an instrumentation for the dynamic measurement of changing head posture. *Am J Orthod Dentofacial Orthop* 1991;99:520-6.

21. Preston CB, Evans WG, Todres JL. The relationship between ortho head posture and head posture measured during walking. *Am J Orthod Dentofacial Orthop* 1997;111:283-7.
22. Usumez S, Orhan M. Reproducibility of natural head position measured with an inclinometer. *Am J Orthod Dentofacial Orthop* 2003;123:451-4.
23. Lundström A, Forsberg CM, Westergren H, Lundström F. A comparison between estimated and registered natural head posture. *Eur J Orthod* 1991;13:59-64.
24. Kylämarkula S, Huggare JÄV. Morphology of the first cervical vertebra in children with enlarged adenoids. *Eur J Orthod* 1985;7:93-6.
25. Huggare JÄV, Raustia A. Head posture and cervicovertebral and craniofacial morphology in patients with craniomandibular dysfunction. *Cranio* 1992;13:435-40.
26. Tecco S, Farronato G, Salini V, Di Meo S, Filippi MR, Festa F, et al. Evaluation of cervical spine posture after functional therapy with FR-2: a longitudinal study. *Cranio* 2005;23:53-66.
27. Cooke MS, Wei SHY. Intersex differences in craniocervical morphology and posture in southern Chinese and British Caucasians. *Am J Phys Anthropol* 1988;77:43-51.
28. Hellsing E, Reigo T, McWilliam J, Spangfort E. Cervical and lumbar lordosis and thoracic kyphosis in 8, 11 and 15-year-old children. *Eur J Orthod* 1987;9:129-38.
29. Peng L, Cooke MS. Fifteen-year reproducibility of natural head posture: a longitudinal study. *Am J Orthod Dentofacial Orthop* 1999;116:82-5.
30. Kapust AJ, Sinclair PM, Turley PK. Cephalometric effects of face mask/expansion therapy in Class III children: a comparison of three age groups. *Am J Orthod Dentofacial Orthop* 1998;113:204-12.
31. Yüksel S, Uçem TT, Keykubat A. Early and late facemask therapy. *Eur J Orthod* 2001;23:559-68.
32. Merwin D, Ngan P, Hägg U, Yiu C, Wei SH. Timing for effective application of anteriorly directed orthopedic force to the maxilla. *Am J Orthod Dentofacial Orthop* 1997;112:292-9.
33. Taylor M, Hans MG, Strohl KP, Nelson S, Broadbent BH. Soft tissue growth of the oropharynx. *Angle Orthod* 1996;66:393-400.
34. Hartsook JT. Mouth breathing as a primary etiologic factor in the production of malocclusion. *J Dent Child* 1946;13:91-4.
35. Ceylan I, Oktay H. A study of the pharyngeal size in different skeletal patterns. *Am J Orthod Dentofacial Orthop* 1995;108:69-75.
36. Hiya S, Suda N, Suzuki MI, Tsuiki S, Ogawa M, Suzuki S, et al. Effects of maxillary protraction on craniofacial structures and upper airway dimension. *Angle Orthod* 2002;72:43-7.
37. Oktay H, Ulukaya E. Maxillary protraction appliance effect on the size of the upper airway passage. *Angle Orthod* 2008;78:209-14.
38. Sayınsu K, Işık F, Arun T. Sagittal airway dimensions following maxillary protraction: a pilot study. *Eur J Orthod* 2006;28:184-9.
39. Kılınc AS, Arslan SG, Kama JD, Ozer T, Dari O. Effects on the sagittal pharyngeal dimensions of protraction and rapid palatal expansion in Class III malocclusion subjects. *Eur J Orthod* 2008;30:61-6.
40. Kaygısız E, Tuncer BB, Yüksel S, Tuncer C, Yıldız C. Effects of maxillary protraction and fixed appliance therapy on the pharyngeal airway. *Angle Orthod* 2009;79:660-7.
41. Mucedero M, Baccetti T, Franchi L, Cozza P. Effects of maxillary protraction with or without expansion on the sagittal pharyngeal dimensions in Class III subjects. *Am J Orthod Dentofacial Orthop* 2009;135:777-81.
42. Baccetti T, Franchi L, Mucedero M, Cozza P. Treatment and post-treatment effects of facemask therapy on the sagittal pharyngeal dimensions in Class III subjects. *Eur J Orthod* 2010;32:346-50.
43. Gungor AY, Turkkahraman H. Effects of airway problems on maxillary growth: a review. *Eur J Dent* 2009;3:250-4.
44. Pae EK, Lowe AA, Sasaki K, Price C, Tsuchiya M, Fleetham JA. A cephalometric and electromyographic study of upper airway structures in the upright and supine positions. *Am J Orthod Dentofacial Orthop* 1994;106:52-9.
45. Odeh M, Schanall R, Gavrieli N, Oliven A. Dependency of upper airway patency on head position: the effect of muscle contraction. *Respir Physiol* 1995;100:239-44.